



FOOT

The surgical treatment of Morton's neuroma[☆]

Samrendu K. Singh, James P. Ioli, Christopher P. Chiodo*

Brigham Foot and Ankle Service, Department of Orthopaedic Surgery, 1153 Centre Street, Suite 56, Jamaica Plain, Boston, MA 02130, USA

KEYWORDS

Morton's neuroma;
Surgery;
Release;
Metatarsalgia

Summary Morton's neuroma is a painful forefoot disorder caused by thickening and fibrosis of an interdigital nerve. The aetiology is unknown. On physical examination, care should be taken to differentiate it from metatarsalgia or joint synovitis/instability. The lateral squeeze test is often positive. The sensitivity and specificity of MRI and ultrasound for confirming the diagnosis has been questioned. Surgery is considered if symptoms persist after 3 months of non-operative treatment.

In this article we describe our recommended surgical technique for neuroma resection.

© 2005 Elsevier Ltd. All rights reserved.

Introduction

Lewis Durlacher,¹ the surgeon chiropodist to Queen Victoria, was actually the first to describe a "form of neuralgic affection" involving the "plantar nerves between the third and fourth metatarsal bones" in 1845. In 1876, Thomas G. Morton,² a Philadelphia based surgeon, further localised the problem to the region of the fourth metatarsophalangeal joint.

While Morton's neuroma is a relatively common painful disorder of the forefoot characterized by thickening and fibrosis of an interdigital nerve, its aetiology and pathogenesis is not entirely under-

stood. Morton speculated that a neuroma or hypertrophy of the digital branches of the lateral plantar nerve was the cause of the pain. Betts³ subsequently attributed the condition to a "neuritis of the interdigital nerve." Nissen⁴ suggested that pressure on the digital artery from local structures causes intermittent neural ischaemia. Betts proposed that a communicating branch to the fourth web space tethers the interdigital nerve of the third web space, rendering the nerve vulnerable to repetitive shear on the edge of the intermetatarsal ligament. Other proposed aetiologies for interdigital neuroma formation include entrapment of the interdigital nerve at the anterior edge of the transverse intermetatarsal ligament⁵ and compression of the interdigital nerve by a swollen intermetatarsal bursa.⁶

The current authors speculate that it may be a combination of peripheral entrapment, tethering, ischaemia and repetitive trauma that is ultimately

[☆]Work undertaken at the Brigham and Women's Hospital, Harvard Medical School, Boston, MA, USA.

*Corresponding author. Tel.: +1 617 983 7361; fax: +1 617 983 7201.

E-mail address: cchiodo@partners.org (C.P. Chiodo).

responsible for the development of the interdigital neuroma.

Clinical presentation

The diagnosis of Morton's neuroma is based primarily on history and physical examination. It should be considered in all patients with forefoot pain, but establishing an accurate diagnosis can be challenging as several other forefoot conditions have similar clinical presentations.

The typical patient with a Morton's neuroma complains of a sharp, burning pain localized to either the second or third web space or metatarsal interspace. Approximately 80% of neuromas occur in the third web space with the remainder occurring in the second web space. The condition occurs so rarely in the first and fourth web spaces that in these cases an alternative diagnosis should be sought. The pain is usually plantar at the level of the metatarsal heads, and often radiates into the toes and may be associated with distal numbness. Interestingly, one differentiating feature is that a patient with a Morton's neuroma often feels the need to remove the shoe and massage the area.⁷

On examination, maximal tenderness is localized to the involved interspace at the level of the metatarsal heads. Care should be taken to differentiate this tenderness from that felt under the metatarsal heads in metatarsalgia or from that felt over the metatarso-phalangeal joint with synovitis or instability. Thus, the metatarso-phalangeal joint drawer test for instability should routinely be performed.

With a Morton's neuroma, cutaneous sensation may be decreased in the distal distribution of the affected digital nerve. Additionally, the "lateral squeeze test" is often positive. This test is performed by applying plantar and dorsal pressure with the examiner's thumb and index finger to the involved interspace at the level of the metatarso-phalangeal joints while gently squeezing the forefoot with the other hand. It is positive if a palpable or painful click is produced. The pain disappears very suddenly when the compression is relieved. The click is commonly referred to as a "Mulder's click", and is thought to result from the neuroma subluxing between the adjacent metatarsal heads.⁸

The differential diagnosis for Morton's neuroma is extensive and includes metatarsalgia, metatarso-phalangeal synovitis/instability, stress fracture, Freiberg's infraction, infection and tumours. For this reason we recommend routine radiographs of the foot when evaluating a patient with a possible neuroma.

Beyond radiographs, further imaging is usually unnecessary. Recently, the sensitivity and specificity of MRI and ultrasound for confirming the clinical diagnosis of a Morton's neuroma has been questioned.⁹⁻¹¹ Sharp et al.¹² reported 29 histologically confirmed cases that had a physical examination, ultrasound and MRI. In this series, physical examination was the most sensitive and specific modality. The accuracy of ultrasound and MRI was similar and dependent on the size of the lesion. We feel that this is important, as in our experience, the size of the lesion correlates neither with preoperative nor postoperative pain.

Treatment

Non-operative therapy should be attempted for 3 months before proceeding with surgery. Initially, non-steroidal anti-inflammatory medications and shoe wear modification are recommended. The shoe should have a soft upper and a wide toe-box.

Second-line treatment options include metatarsal padding, orthotics, and steroid injections. We inject the web space through the dorsum of the foot. It is essential that the needle be passed deep to the transverse intermetatarsal ligament. This can be confirmed by looking for tenting of the plantar skin.

Surgical excision of a symptomatic neuroma is an effective and reliable treatment option for those patients who have not responded to non-operative measures for a persistently painful neuroma.

Contraindications to surgery include ongoing infection and compromised perfusion. In the foot with poor pulses, Doppler evaluation is a valuable tool to assess perfusion and wound healing capacity. If the ankle/brachial pressure index (ABPI) is less than 0.5, surgery should be delayed, and the patient referred for a vascular opinion.

All surgical candidates should be counseled preoperatively with regard to the general risks of foot surgery and the possibility of developing a symptomatic "stump" or "bulb" neuroma, and warned that there will be permanent numbness in the affected webspace.

Surgical treatment

Several procedures have been described^{13,14} including isolated inter-digital nerve excision, isolated transverse metatarsal ligament division, and inter-digital nerve excision combined with transverse ligament division.

Our preference is nerve resection with intermetatarsal ligament division, as there is little evidence supporting simple ligament division. We do not favour resection without ligament division, as the painful stump cannot be buried sufficiently proximally. The concern that division of this ligament may lead to a splayed foot has been disproved.¹⁵

Dorsal approach

For primary surgery, a dorsal approach is to be preferred. The patient is positioned supine and local or regional anesthesia used. An ankle or thigh tourniquet may be used.

A three to four centimeter longitudinal incision is made in the midline of the involved interspace. The incision starts proximal to the metatarsal heads and extends distally into the web space.¹⁶ Because the skin in the web space is thin, the distal incision must be adequate to prevent uncontrolled tearing with retraction.

The subcutaneous tissues are bluntly dissected with a finger or the back of a forceps. Just deep to the skin there is a small vein that crosses the field and should be cauterized. Additionally, care should be taken to avoid damaging the dorsal digital nerves.

The deep fascia of the foot is a distinct layer and is divided sharply in line with the skin incision. This layer should not be confused with the deeper, transverse intermetatarsal ligament.

A small self-retaining retractor, or ideally a lamina spreader, is then placed between the metatarsals to put the transverse metatarsal ligament under tension. With this, the proximal and distal borders are readily identified and a blunt elevator or haemostat can be passed deep into it to protect the underlying nerve (Fig. 1). The ligament is then released sharply (Fig. 2).

Next, the two distal branches of the common digital nerve are identified and isolated. After supplemental infiltration of the region with plain lignocaine, the distal branches are transected.

The cut distal ends of the nerve are grasped with a hemostat. The nerve is then gently elevated and dissected proximally. The small plantar branches of the nerve should be identified and divided (Fig. 3). While traction is applied to the nerve, the area is again infiltrated with lignocaine and the nerve is transected as proximal to the metatarsal heads as possible (Fig. 4).

The deep tissues are closed with buried interrupted 4-0 absorbable sutures. The skin is closed with 4-0 nylon sutures using a 'no-touch' technique.

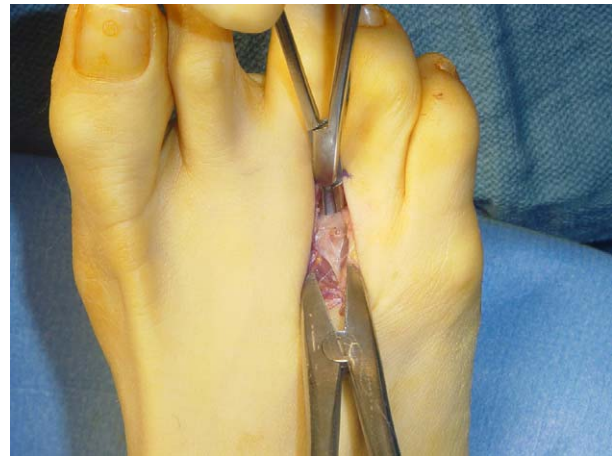

Figure 1 A lamina spreader is placed between the metatarsals to put the transverse metatarsal ligament under tension. A haemostat protects the underlying nerve.

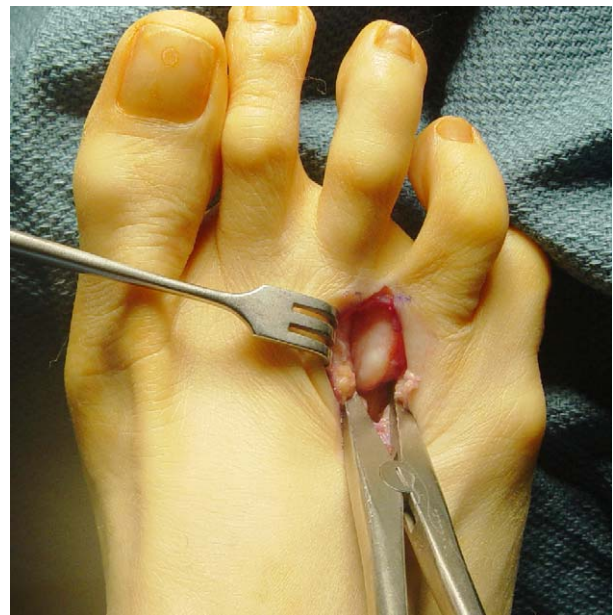

Figure 2 The transverse metatarsal ligament has been divided revealing the neuroma.

Plantar approach

A symptomatic stump neuroma may develop in patients who have undergone a primary interdigital neurectomy.^{17,18} This is characterized by plantar burning or a stabbing pain that is exacerbated by weight bearing and reproduced by applying plantar pressure just proximal to the metatarsal heads. For resection of a recurrent stump neuroma, a plantar approach is recommended, as this will allow better exposure of the proximal nerve trunk.^{19,20}

A plantar incision is made just proximal to the web space and extends at least 4 cm proximally, equidistant between the metatarsal heads and shafts.

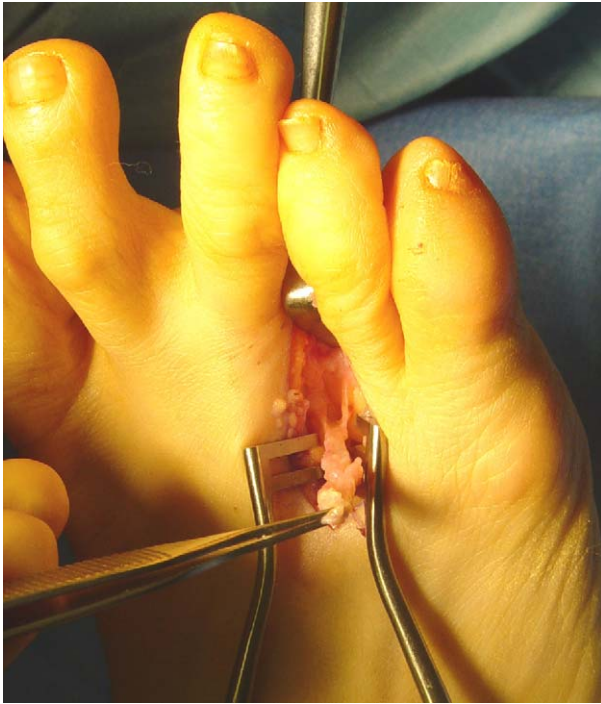

Figure 3 The cut distal ends on the nerve are grasped with a haemostat. The nerve is gently elevated and dissected proximally. The small plantar nerves should be identified and divided.

Minimal deep dissection is needed, as the neuroma is usually located subcutaneously (Fig. 5).

The neuroma is dissected and freed from adjacent tissues. Dissection is then continued proximally to a normal segment of the nerve trunk.

At this level, the nerve is transected sharply and the proximal stump buried into the intrinsic musculature of the foot.

The deep tissues are closed with buried interrupted 4-0 absorbable sutures. The skin is closed with 4-0 nylon sutures.

Post-operative care and return to activity

In all cases, a compression dressing is applied and the foot protected with a post-operative shoe. After primary neurectomy through a dorsal approach, immediate weight bearing is allowed and the skin sutures are removed at 10–14 days post-operatively. After revision neurectomy through a plantar approach, weight bearing and suture removal are delayed for 2–3 weeks.

Cross training for high-level athletes should be delayed until the skin has healed.

Thereafter, appropriate exercises include pool training and the use of an exercise bike. The patient may progress to a regular shoe in 3–4 weeks. High-level sports participation is generally restricted for 4–6 weeks.

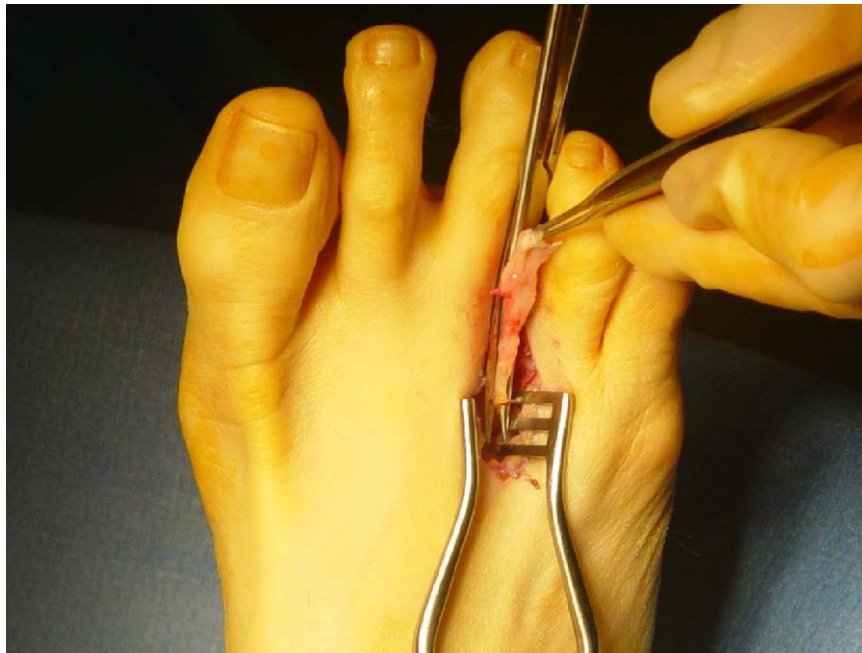


Figure 4 Traction is applied and the nerve transected as proximally to the metatarsal heads as possible.

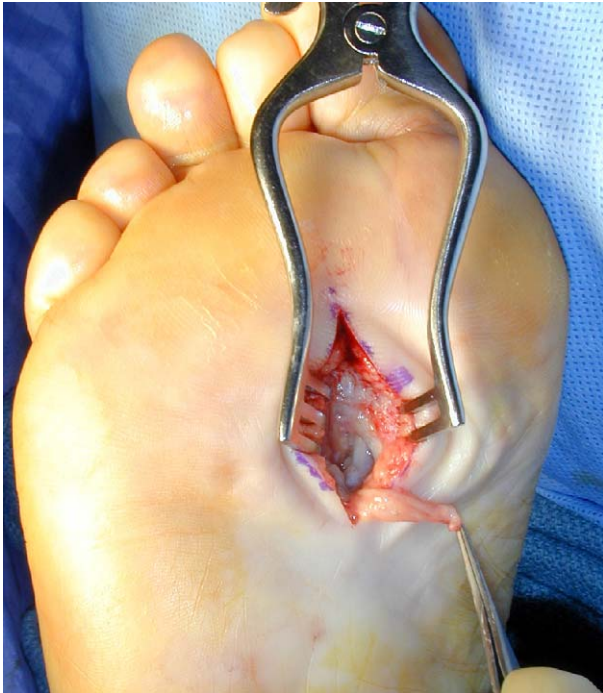

Figure 5 The plantar approach for revision surgery. The nerve is subcutaneous.

Pearls and pitfalls

Careful handling of the soft-tissues and meticulous haemostasis will minimize post-operative swelling and pain.

Good knowledge and understanding of the local anatomy and good surgical exposure is essential to avoid damaging and/or mistakenly excising the lumbrical tendon or the digital artery. Exposure is facilitated by an adequate incision, the use of a tourniquet, and loupe magnification.

Placing a self-retaining retractor or lamina spreader between the metatarsal heads puts the intermetatarsal ligament under tension, greatly facilitating identification and division of this structure.

Transection of the nerve trunk as proximal to the metatarsal heads as possible decreases the chances of developing a painful "stump" neuroma. To this end, dividing the small plantar branches of the nerve proximal to the level of transection allows the proximal segment to retract more readily.

With burial of a recurrent stump neuroma into the intrinsic musculature of the foot, it is helpful to place a 4-0 absorbable stitch through the epineural layer of the distal aspect of the proximal nerve segment. The suture is attached to a straight free needle, which is then delivered through the dorsum of the foot. This pulls and buries the proximal nerve

segment deep within the intrinsic musculature of the foot. The absorbable suture is then cut under tension at the level of the dorsal skin and allowed to retract subcutaneously.

Conclusion

Reports in the literature on patient satisfaction following this procedure range from 80% to 93%.^{14,17,18,21} Patients should be counseled about the specific residual effects including interdigital numbness (68%¹⁷, 72%¹⁸) and plantar numbness (50%¹⁷, 65%¹⁸).

Practice points

- Morton's neuroma is a common cause of forefoot pain.
- The diagnosis is based primarily on history and physical examination.
- Surgery should be considered only after 3 months of non-operative therapies have failed.
- We recommend a dorsal approach with division of the transverse intermetatarsal ligament and neuroma resection.

References

1. Durlacher L. *A treatise on corns, bunions, the diseases of nails, and the general management of feet*. Simpkin: Marshall and Co; 1945.
2. Morton TG. A peculiar and painful affection of the fourth metatarso-phalangeal articulation. *Am J Med Sci* 1876; 71:37–45.
3. Betts LO. Morton's metatarsalgia. *Med J Aust* 1940;1:514–5.
4. Nissen KI. Plantar digital neuritis: Morton's metatarsalgia. *J Bone Joint Surg (Br)* 1948;30:84–94.
5. Gauthier G. Thomas Morton's disease: a nerve entrapment syndrome. A new surgical technique. *Clin Orthop Relat Res* 1979;142:90–2.
6. Bossley CJ, Cairney PC. The intermetatarsal bursa: its significance in Morton's metatarsalgia. *J Bone Joint Surg (Br)* 1980;80-B:184–7.
7. Lutter LD. *Atlas of adult foot and ankle surgery*. St Louis, Missouri: Mosby; 1997. p. 115–20.
8. Mulder JD. The causative mechanism in Morton's metatarsalgia. *J Bone Joint Surg (Br)* 1951;33-B:94–5.
9. Terk MR, Kwong PK, Suthar M, Horvath BC, Colletti PM. Morton neuroma: evaluation with MR imaging performed with contrast enhancement and fat suppression. *Radiology* 1993;189:239–41.
10. Resch S, Stenstrom A, Jonsson A, Jonsson K. The diagnostic efficacy of magnetic resonance imaging and ultrasonography

- in Morton's neuroma: a radiological-surgical correlation. *Foot Ankle Int* 1994;15:88-92.
11. Zanetti M, Strehle JK, Zollinger H, Hodler J. Morton neuroma and fluid in the intermetatarsal bursae on MR images of 70 asymptomatic volunteers. *Radiology* 1997;203:516-20.
 12. Sharp RJ, Wade CM, Hennessy MS, Saxby TS. The role of MRI and ultrasound imaging in Morton's neuroma and the effect of size of lesion on symptoms. *J Bone Joint Surg (Br)* 2003;85-B:999-1005.
 13. McGlamry ED, Banks AS, Downey MS. *Comprehensive textbook of foot surgery*. Baltimore: Williams & Wilkins; 1992. p. 304-20.
 14. Thomson CE, Gibson JN, Martin D. Interventions in the treatment of Morton's neuroma. *Cochrane Database Syst Rev* 2004;(3):CD003118.
 15. Hamilton WG. Morton's neuroma surgery. *The Foot: Surgical Update*. Seattle, Washington: AAOS Summer Institute; 1992.
 16. McKeever DC. Surgical approach for neuroma of plantar digital nerve (Morton's Metatarsalgia). *J Bone Joint Surg* 1952;34A:490.
 17. Mann RA, Reynolds JC. Interdigital neuroma—a critical clinical analysis. *Foot Ankle* 1983;3:238-43.
 18. Coughlin MJ, Pinsonneault T. Operative treatment of interdigital neuroma: a long-term follow-up study. *J Bone Joint Surg* 2001;83A:1321-8.
 19. Johnson JE, Johnson KA, Unni KK. Persistent pain after excision of an interdigital neuroma. Results of reoperation. *J Bone Joint Surg Am* 1988;70:651-7.
 20. Beskin JL, Baxter DE. Recurrent pain following interdigital neurectomy—a plantar approach. *Foot Ankle* 1988;9:34-9.
 21. Keh R, Ballew K, Higgins K, Odom R, Harkless L. Long term follow-up of Morton's neuroma. *J Foot Surg* 1992;31(1): 93-5.

Available online at www.sciencedirect.com

